

Kimura et. al., ¹⁹F Magnetic resonance imaging of perfluorooctanoic acid encapsulated in liposome for biodistribution measurement, *Magnetic Resonance Imaging* 22: 855-860, 2004

Executive Summary

The motivation of this paper is to visualize of the tissue distribution of perfluorooctanoic acid (PFOA, C₇F₁₅COOH) by ¹⁹F-MRI for pharmacological studies of similar compounds since they have been used for blood substitute and exhibited *in vivo* toxicity to industrial workers despite of their numerous applications. In general, the wide-range distribution of chemical shifts of ¹⁹F-containing metabolites can be used for molecular imaging and tissue function evaluations. Furthermore, ¹⁹F-MRI using ¹⁹F-containing compounds has the potential for image contrast enhancement because (1) there is no background of ¹⁹F signal in biological systems (¹⁹F signal is the contrast for ¹H-MR image that provides anatomy information); (2) ¹⁹F has the next highest MR sensitivity (83% of ¹H); and (3) current ¹H-MRI scanners can be used for ¹⁹F-MRI without expensive hardware adjustment. The challenges intrinsic to ¹⁹F-MRI are (1) ¹⁹F has Long T1 (resulting in long acquisition time) and short T2 (causing signal attenuation); (2) chemical shifts of ¹⁹F-NMR cause chemical shift image artifacts (although preferred to trace the metabolism); and (3) signal can only be obtained from the agents retained in tissue (SNR is the major concern for ¹⁹F-MRI though one perfluorocarbon molecule contains many ¹⁹F nuclei).

To face these challenges, the authors exploited the chemical shift selected fast spin-echo (FSE) method to successfully trace the tissue distribution of PFOA by ¹⁹F-MRI and ¹H-MRI. Chemical shift

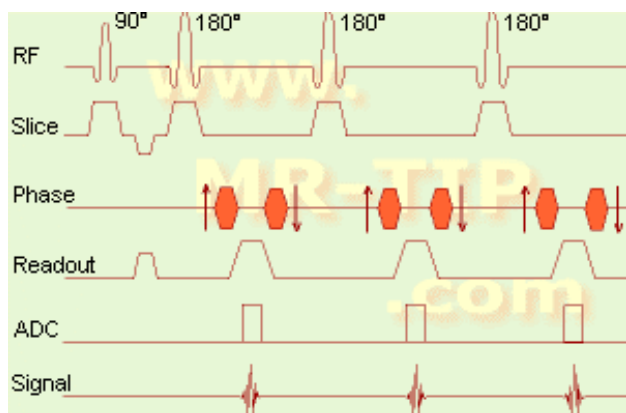


Figure 1. FSE pulse sequence timing diagram

Courtesy of www.MR-TIP.com. Used with permission.

selected RF pulse to excite only the -CF₃ group of PFOA was made possible because of the large chemical shift between -CF₃ and the other -CF₂ groups, which exceeded 35 ppm (10 times that of fat and water ¹H). AT 9.4 T (376.3 MHz), this gives a frequency difference of about 14 kHz. Chemical shift selection not only eliminated chemical shift artifacts but also rid of the signal intensity modulation caused by J-coupling from adjacent ¹⁹F atoms. To preserve ¹⁹F MR signal, spin echo was used due to the short T2 of -CF₃ of PFOA *in vivo* because gradient echo would cause severe T2* effect and the ¹⁹F MR signal would be lost even faster. To shorten the acquisition time of ¹⁹F-MRI with long T1 of ¹⁹F, fast spin echo (FSE) sequence was utilized. Figure 1 illustrates the timing of FES sequence. The # of echoes (or # of 180° RF pulses) per repetition is called the echo train length (ETL). The acquisition time was shortened because multiple phase-encoding steps with a single excitation (90° RF) followed by multiple echoes (180° RF) were carried out so that the acquisition time is reduced proportional to ETL. Effective echo time (TE) = last (maximum) echo time/ETL.

The *in vivo* relaxation times, T1 and T2, of -CF₃ of PFOA were measured by inversion recovery (IR) and Carr-Purcell-Meiboom-Gill (CPMG) methods respectively. As discussed in class, IR doubles the dynamic range for more accurate T1 measurement. In HW#2-P3, we learned that the CPMG method corrects the refocusing pulse error if any at even echoes to ensure the accurate measure of T2. It was determined that both T1 and T2 were shortened *in vivo* due to molecular motion restriction of PFOA molecules, especially the -CF₃ groups. T2 of water ¹H ranges from several tens to hundreds of ms; while T2 of -CF₃ group of PFOA is less than 10 ms (6.3 ms) *in vivo*. Short T2 (2.3 ms) observed in

PFOA-liposome solution was probably due to high solution viscosity. Fortunately, short *in vivo* T1 of PFOA enabled the shortening of acquisition time so that image quality was improved by data averaging. The *in vivo* ¹⁹F-MR image was obtained in 12 min.

To optimize *in vivo* ¹⁹F-MRI parameters, *in vitro* ¹⁹F-MRI was done on PFOA-liposome solution in an NMR tube (9.4 T, effective TE = 1ms). Both the images obtained and k-space data confirmed that ETL = 2 is more effective than ETL = 4. The image of ETL = 4 gives better edge definition of the NMR tube than that of ETL = 2. Correspondingly, in k-space, the signal amplitude with ETL = 2 is clearer in the high spatial frequency domain, which contains high-resolution information of the image, than that of ETL = 4. Given that T2 of -CF₃ of PFOA in liposome solution is 2.3 ms and effective TE is 1 ms, for ETL = 4, the last two echoes were collected at 3 and 4 ms when the transverse magnetization amplitude of ¹⁹F should have been very small. Thus, these data collection would not contribute much to the signal but rather cause noise accumulation, which could be the reason why ETL = 4 turned out to be less effective than ETL = 2. To effectively collect data and shorten the image acquisition time, it is necessary to use strong and rapidly switching gradients given that the maximum TE is less than 10 ms, which was difficult to implement under instrumental limitations. Thus, ETL = 2 was used as the optimal value for *in vivo* ¹⁹F-MRI.

After 1 mL of PFOA-liposome solution was orally administered to mice (fasted for 4 hr), ¹H-MR image and a series of ¹⁹F-MR images were collected at 0.4, 0.6, 1.0, 1.3, 1.6, 1.8, 2.4, and 2.7 hr. Typical ¹⁹F-MRI conditions are: 9.4T (376.2 MHz); chemical shift selection - Gaussian pulse with 9kHz band width; TR = 0.15 s; effective TE = 1 ms; ETL = 2; 64 x 16 data points; FOV = 8cm x 4cm; no slice selection; acquisition time = 12min. ¹H and ¹⁹F -MR coronal images were combined and it was observed that PFOA that initially existed in the mouse stomach began to distribute into the liver 1 hour after the administration of PFOA; after 2.7 hr, PFOA was transferred mostly from the stomach to the liver. After ¹⁹F-MRI, mice were sacrificed and the organs were excised and cut into pieces for ¹⁹F-NMR, in which the signal intensity of -CF₃ of PFOA from different organs was measured and calibrated by signal from benzene solution of trifluoroacetamide (CF₃CONH₂) for quantification. With this quantification, the lowest concentration of PFOA that ¹⁹F-MRI was able to visualize was estimated from the images to be about 1 μmol PFOA / g tissue. If we assume a tissue density of 1g/mL, this concentration is about 1 mM of PFOA in tissue, which is 5 orders of magnitude less than that of water ¹H concentration (~100M).

In conclusion, tissue distribution of PFOA was successfully traced by ¹H and ¹⁹F -MRI, the latter of which used chemical shift selected fast spin-echo method. It was necessary to administer PFOA at high concentration of 100 mg (0.19 mmol)/kg body weight, corresponding to 20 times the dose using radiolabel method, confirming that the major challenge for ¹⁹F-MRI is SNR. Contrast agents that elongate T2 and shorten T1 are desirable.

Based upon this study, the following questions are of interest to me. (1) Would you use ETL = 3 or 4 for *in vivo* ¹⁹F-MRI since T2 = 6.3ms instead of 2.3ms? (2) If the acquisition time is 12 min (0.2 hr) and PFOA is moving, what actual states do the images at 0.4, 0.6, 1.0 hr ... represent? (3) Is FSE is the optimal sequence for ¹⁹F-MRI? (4) How to make use of all the ¹⁹F nuclei in PFOA instead of -CF₃ only since the concentration of PFOA is the major limiting factor?

Finally, I very much enjoyed this course. Grateful thanks to you all!

Jin May 17, 2006