

Harvard-MIT Division of Health Sciences and Technology
HST.121: Gastroenterology, Fall 2005
Instructors: Dr. Jonathan Glickman

Non-neoplastic diseases of the esophagus

Esophageal diverticula

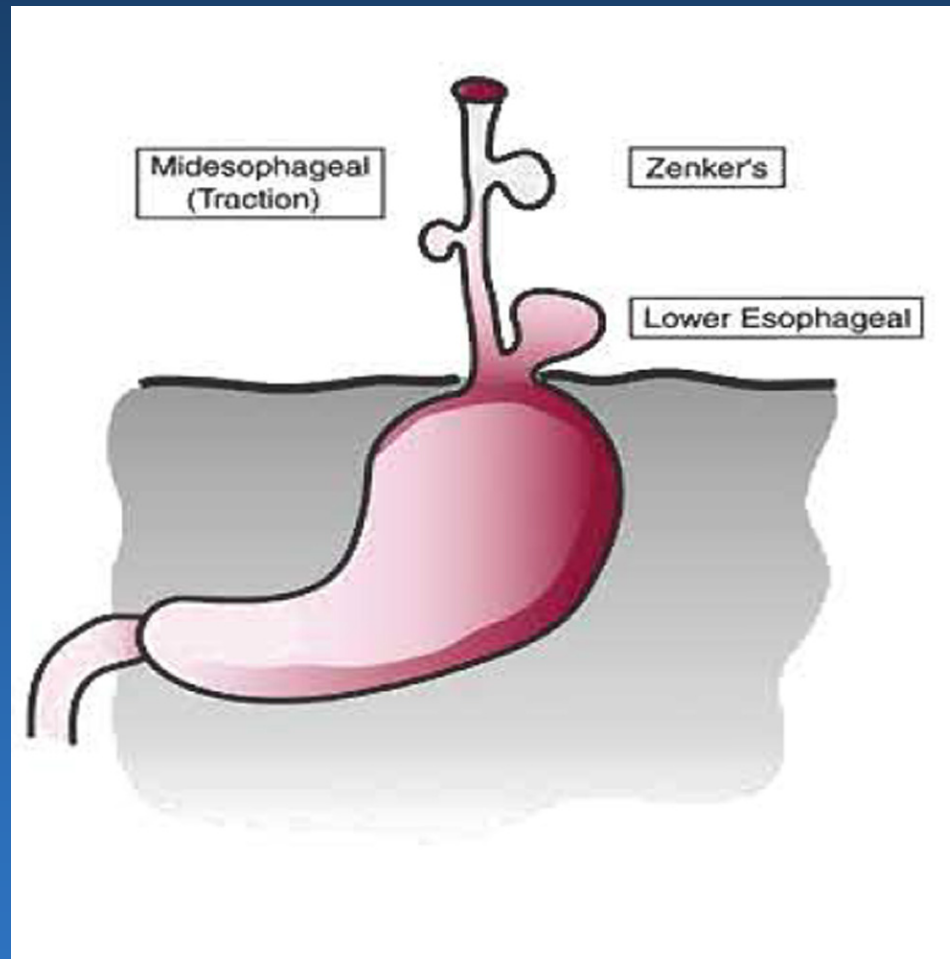


Image by MIT OCW

Zenker's diverticulum

Image removed due to copyright reasons.

Esophagus- hiatal hernias

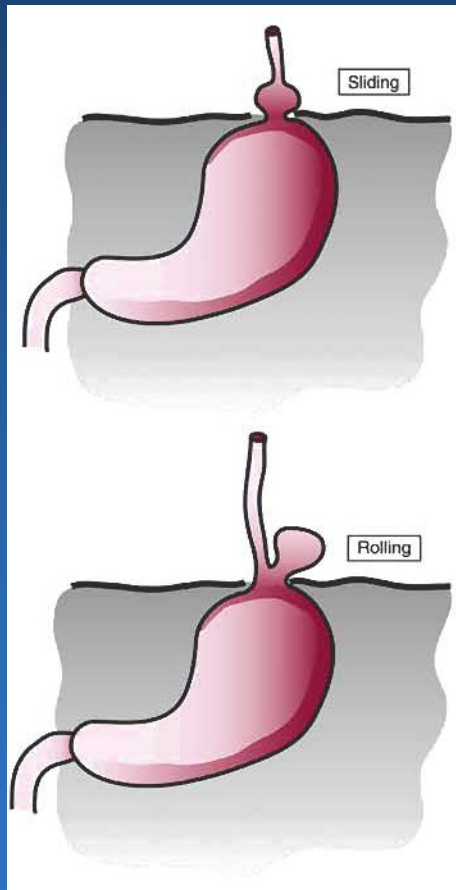


Image by MIT OCW

Esophagitis- classification

- **Reflux**
- **Infectious: viral, fungal**
- **Allergic**
- **Drug-related**
- **Physical: Radiation, pill, corrosive agents**
- **Achalasia**
- **Systemic disorders: Crohn's, GVHD, sarcoidosis, scleroderma**

Reflux esophagitis- gross

Figure removed due to copyright reasons. Please see:

Rosai, Juan. *Rosai and Ackerman's Surgical Pathology*. 9th ed. New York, NY: Elsevier Health Sciences, 2004. ISBN: 0323013422.

Active esophagitis- histology

- **Basal zone hyperplasia**
- **Spongiosis**
- **Elongated papillae (>75%)**
- **Intraepithelial PNMs and/or eosinophils**
- **Surface erosion or ulceration**

Zenker's diverticulum

Image removed due to copyright reasons.

Achalasia

- **Unknown etiology**
- **Defect in peristalsis and LES relaxation**
- **Similar physiology to Chagas' disease**
- **Distal esophageal narrowing**
- **Risk factor for squamous cell CA**